


Vol 22, No. 4, July - August 2012

# INDIAN JOURNAL OF NEPHROLOGY

## Highlights of the Issue

- Deflazacort in comparison to other steroids
- Periodontal status in patients
- Causes of death in renal transplant



Official Publication of the Indian Society of Nephrology

Free full text at  
[www.indianjnephrol.org](http://www.indianjnephrol.org)

# Acute renal failure due to bilateral ureteric necrosis following percutaneous chemical lumbar sympathectomy

P. Ranjan, J. Kumar, S. S. Chipde

Department of Urology and Kidney Transplantation, Sanjay Gandhi Post Graduate Institute of Medical Sciences, Lucknow, India

## ABSTRACT

We report a case of acute renal failure as a result of obstructive uropathy as a consequence of instillation of phenol used for chemical sympathectomy in Beurger's disease of the lower limbs. Extensive bilateral ureteral necrosis occurred as a result of phenol instillation that. Such practices are still common among the general surgeons and such a complication has not been described before.

**Key words:** Acute renal failure, Beurger's, chemical, injury, lumbar, percutaneous, sympathectomy, ureteric

## Introduction

Percutaneous lumbar sympathectomy (PCLS) is a popular treatment for Beurger's disease affecting the toes. Although PCLS with or without radiological guidance is a minimally invasive technique to chemically block the lumbar sympathetic ganglia with phenol injection but inadvertent damage to adjacent structures is a matter of concern.<sup>[1]</sup> Unilateral ureteral injury leading to stricture following PCLS is rare but known complication.<sup>[2]</sup> We herein report a patient who developed acute renal failure due to bilateral ureteric necrosis and stricture following PCLS for Beurger's disease.

## Case Report

A 70-year-old nondiabetic, nonhypertensive gentleman, smoker for 12 years presented to the emergency department with renal failure. History revealed

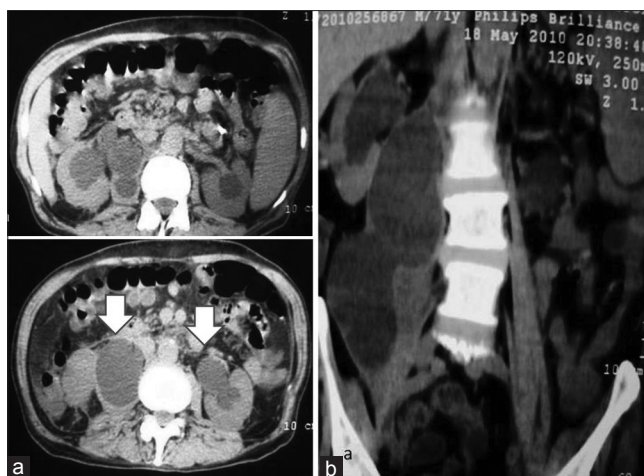interventional treatment for Beurger's disease in the form of toe amputation and bilateral injections for percutaneous chemical lumbar sympathectomy 6 months back. At admission he had loss of appetite, intractable vomiting, and fever for 15 days, and progressive oligoanuria for the last 6 days. His serum creatinine was 6.5 mg/dL, hemoglobin 6.2 gm%, TLC 24000/cmm and blood gases revealed severe metabolic acidaemia with a base deficit of 10. An abdominal sonography revealed bilateral gross hydronephrosis with dilated upper ureter on both sides along with a collection in the region of the right psoas muscle, possibly due to urinoma. A noncontrast computed tomography scan revealed gross hydronephrosis on both the sides with atrophic and thin renal parenchyma on the right side along with the urinoma over the right psoas [Figure 1]. He was dialyzed; metabolic abnormalities were corrected and then bilateral percutaneous nephrostomies and a percutaneous drain in the right psoas collection were placed. After achieving an initial postobstructive diuresis the daily output from right nephrostomy stabilized at 400 mL and from left nephrostomy achieved an output of 1500 mL per day with hardly any output from the urethra. The psoas collection initially drained 500 mL of purulent uriniferous collection and then subsided. The general condition of the patient improved following conservative treatment and his creatinine dropped to 1.8 mg%, after control of sepsis.

In the operating room, bilateral retrograde ureteropyelogram and simultaneous bilateral nephrostogram under fluoroscopy was performed to delineate the length of ureteric obstruction. It revealed upper-right ureteric stricture of length about 6–8 cm and upper-left ureteric

### Address for correspondence:

Dr. Priyadarshi Ranjan, Department of Urology and Kidney Transplantation, Sanjay Gandhi Post Graduate Institute of Medical Sciences, Lucknow, India. E-mail: priyadarshiranjan@sify.com

Access this article online	
Quick Response Code:	Website: www.indianjnephrol.org
	DOI: 10.4103/0971-4065.101252



**Figure 1:** (a) A noncontrast CT scan showing bilateral Hydronephrosis (right>left) and a urinoma over the psoas muscle on the right side due to rupture of the calyx/fornices as a result of ureteric obstruction, with dilated upper ureter on left side. (b) Axial view of the same

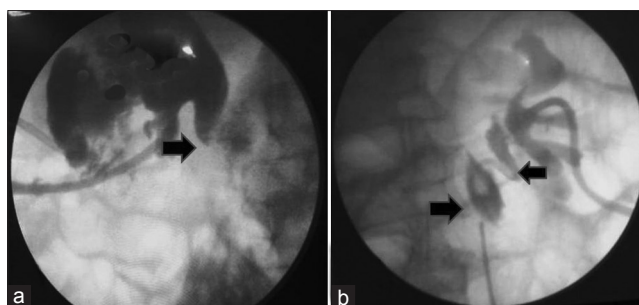
stricture of about 2–3 cm [Figure 2]. The glomerular filtration rate (GFR) of the right kidney was 6 mL/min and 34 mL/min of the left side.

He was explored on the better functioning side first and approximately 4–5 cm of the upper-left ureter was found necrotic and fibrosed, as against 2–3 cm defect depicted by the dye study. It was obliterated and had dense adhesions in the periureteric area presumably secondary to absolute alcohol injection. After renal descensus and ureteric mobilization an end to end uretero-ureterostomy was done over a 6 F ureteric stent. On the other side approximately 10–12cm of upper ureter was found to be necrotic and oblitative and almost the entire upper ureter was strictured. The histopathology of the segment of ureter was sent and revealed only inflammatory cells with few areas of fibrous tissues. No malignancy was noted.

In view of poorly functioning right kidney with a GFR of 6 mL/min, and advanced age of the patient, extensive reconstruction of the ureter was not considered and right nephrectomy was done. In the post-op period, patient developed adhesive intestinal obstruction, which was managed by exploratory laparotomy and adhesiolysis. Following this, patient recovered and was discharged 12 days later. He maintains a serum creatinine level between 1.4–1.8mg% after 1 year of follow up and is asymptomatic.

## Discussion

Most iatrogenic ureteric injuries, complete or partial ureteric transection, and less commonly ureteric necrosis,<sup>[3]</sup> can complicate several surgical and percutaneous procedures. If detected intraoperatively on the table, they can be repaired immediately as the



**Figure 2:** (a) Nephrostogram on right side shows complete block at around UPJ. (b) Nephrostogram with simultaneous RGP on the left side shows urinoma and approximately 3–4cm loss of the upper-left ureter around the pelvi ureteric junction

tissues are healthy and supple. However, when these injuries are missed during surgery and noticed only days or weeks later, the patient develops symptoms from ureteric obstruction, colic, urinoma, or abscess formation, flank pain, fever, urosepsis, acute renal failure if bilateral. As an initial treatment external drainage of the renal pelvis by nephrostomy and the urinoma or abscess is usually established.<sup>[4]</sup> The further management of these patients depends on the location and the extent of the ureteric loss. Antegrade or retrograde placement of an indwelling ureteric stent is usually attempted in short ureteric narrowing, if the defect is nonoblitative, but with long segmental obliteration, complex open surgical repair has to be done. If the patient is regarded as unsuitable for such an operation, and the contralateral kidney functions normally, sometimes even nephrectomy is preferred.<sup>[4]</sup> Options include uretero-ureterostomy, uretero-pyelostomy, uretero-calycostomy, and ileal transposition depending upon length of stricture. Boari flap and psoas hitch are usually not the options as the injury following PCLS usually involves upper ureter around first to third lumbar vertebra. Since the patient landed up into nephrectomy of one side and is an old patient, any procedure that has more morbidity is not advisable. But it is important that such a patient should be monitored and followed strictly.

These complications are due to imprecise deposition and unpredictable spread of injected chemicals too far beyond the needle tip.<sup>[5]</sup> Ureteral stricture following PCLS is an occasionally reported entity. Arteritis of ureteral vessels causing ischemia of ureter is not known in the literature and the possibility is thoughtful but not fitting to our case as we have a cause for the ureteric necrosis in our patient. Acute renal failure secondary to bilateral ureteric injury following PCLS is not reported in literature till now. High index of suspicion should be made for bilateral ureteric injury in a patient who presents with acute renal failure and has a history of percutaneous intervention for chemical sympathectomy for peripheral vascular disease.

Unilateral injury may go undetected as the ipsilateral kidney may undergo atrophic changes secondary to chronic obstruction. Stricture due to ureteral ischemia following chemolysis due to phenol injection in retroperitoneum is a slow, steady, and time taking phenomenon, as it occurs due to development of fibrosis around ureter. Such slow and steady disease process usually present late.

## References

1. Boas RA. Sympathetic nerve blocks: in search of a role. *Reg Anaesth Pain Med* 1998;23:292-305.
2. Dowling RA, Corriere JN Jr, Sandler CM. Iatrogenic ureteral injury.

*J Urol* 1986;135:912-5.

3. Trigaux JP, Decoene B, Van Beers B. Focal necrosis of the ureter following CT-guided chemical sympathectomy. *Cardiovasc Intervent Radiol* 1992;15:180-22.
4. Lask D, Abarbanel J, Luttwak Z, Manes A, Mukamel E. Changing trends in the management of iatrogenic ureteral injuries. *J Urol* 1995;154:1693-54.
5. Dirim A, Kumsar S. Iatrogenic ureteral injury due to lumbar sympathetic block. *Scand J Urol Nephrol* 2008;42:395-6.

**How to cite this article:** Ranjan P, Kumar J, Chipde SS. Acute renal failure due to bilateral ureteric necrosis following percutaneous chemical lumbar sympathectomy. *Indian J Nephrol* 2012;22:292-4.

**Source of Support:** Nil, **Conflict of Interest:** None declared.