

available at www.sciencedirect.com
journal homepage: www.europeanurology.com



European Association of Urology



Female Urology - Incontinence

Supratrigonal VVF Repair by Modified O'Connor's Technique- An Experience of 26 Cases

Divakar Dalela^a, Priyadarshi Ranjan^{b,*}, Pushpa Lata Sankhwar^c,
Satya N. Sankhwar^a, Vineet Naja^a, Apul Goel^a

^aDepartment of Urology, King George Medical University, Lucknow, UP, India

^bDepartment of Surgery, King George Medical University, Lucknow, UP, India

^cDepartment of Obstetrics and Gynecology, King George Medical University, Lucknow, UP, India

Article info

Article history:

Accepted December 13, 2005

Published online ahead of
print on ●●●

Keywords:

Supratrigonal
Vesico-vaginal fistula
Cystotomy

Abstract

Objective: To report the technical modifications of O'Connor's procedure and their outcome in 26 supratrigonal vesico vaginal fistulae.

Materials and methods: Twenty-six cases of supratrigonal VVF (17 primary, 9 recurrent) were operated using the described modifications. It consisted of approaching the bladder transperitoneally, without dissecting the retropubic space, making a short sagittal or parasagittal cystotomy in between stay sutures, liberal use of bladder rotation flaps instead of midline closure, using single layer, continuous, closely placed, interlocking stitches for bladder as well as vaginal approximation and universal use of vascularised tissue interposition.

Results: Mean fistula size was 2.8 cm (range 1.0 to 3.7). Mean operative time was 104 minutes, and blood loss was insignificant. Three patients required ureteroneocystostomy. All patients were dry after 2–3 weeks of suprapubic and per urethral catheter drainage. One patient persisted with stress urinary incontinence. No patient on follow up complained of features suggestive of prolonged ileus, peritonitis or adhesive intestinal obstruction.

Conclusion: Modified O'Connor's repair is safe and achieves excellent functional results. It requires a shorter cystotomy instead of bi-valving of the bladder, thus minimizes tissue trauma, intraoperative blood loss and operating time. It also gives option of tailoring the cystotomy in sagittal or parasagittal line, according to the site and size of the fistula, and thus permits closure of fistula by rotation of bladder flap into the defect without any lateral traction on the bladder edges. Retropubic dissection and drainage of the retropubic space is also not required.

© 2005 Published by Elsevier B.V.

* Corresponding author. Sector-20, house-no-25, Indira Nagar, Lucknow, UP 226016, India. Tel. +91 9335211703.

E-mail address: priyadarshiranjan@sify.com (P. Ranjan).

1. Introduction

Vesicovaginal fistula (VVF) is a distressing disease with social, hygienic, urological, and psychosexual consequences. Supratrigonal VVF results from a variety of causes- in west more common is to see iatrogenic fistula, while in developing world obstetric etiology prevails. In the west, 90% cases are caused by inadvertent trauma to the bladder during surgery [1]. Hysterectomy accounts for 75% of such fistulae [2]. Recent meta-analysis by Gilmour suggests that iatrogenic bladder injury occurs in 10.4 per 1000 cases [3].

In developing countries, such fistulae often result following caesarean section for prolonged/complicated obstructed labour where a combination of surgical trauma and ischemia (caused by fetal head compression) jointly contribute to the occurrence of fistula. The variations in the degree of ischemic damage and resultant fibrosis have forced surgeons to modify their techniques to achieve the best results [4].

The O'Connor operation has been the most accepted method of repairing such supratrigonal VVF till date. The traditional O'Connor's technique utilizes suprapubic access for extra-peritoneal dissection of the retropubic space to dissect the urinary bladder, followed by long sagittal cystotomy (bi-valving the bladder) carried till the fistula (Fig. 1). The fistulous tract is then excised followed by two-layered closure after tissue transposition in between the vagina and the bladder walls. Herein we describe our modifications of the O'Connor technique for repairing a supratrigonal VVF using the trans peritoneal approach.

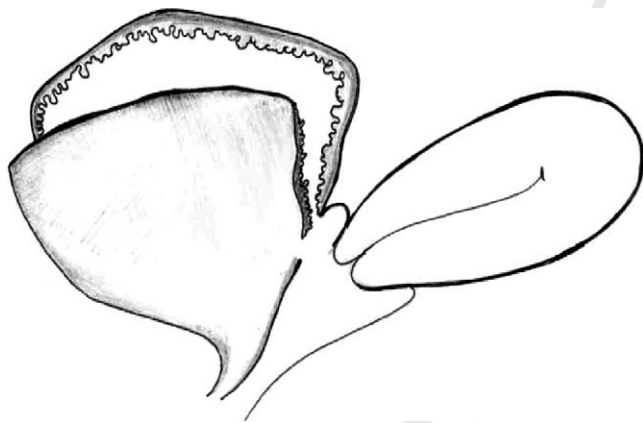


Fig. 1 - Traditional O'Connor's procedure involves a long cystotomy coursing through the anterior wall and dome of the bladder (bi-valving).

2. Materials and methods

Twenty-six patients (17 primary, 9 recurrent) admitted between January 2000 to June 2004 with supratrigonal VVF were operated using these modifications. The interval between the onset of leakage and final surgical correction ranged from 6 weeks to 8 years (median 10 weeks). A detailed medical history was recorded focusing on the cause of fistula and previous attempts at repair. None of the patients had received pelvic irradiation. Two cases had vesical calculus, which was removed by transurethral cystolitholapaxy 2-3 weeks prior to definitive closure. Both these patients had an obstetric fistula. Prior stone removal eliminates the potential source of infection and mucosal edema of the bladder and thus provides optimal bladder tissue for healing of the fistula [5]. We prefer transurethral cystolitholapaxy for such stones owing to its minimally invasive nature and the ability to break even large stones [5].

Vaginal assessment was done to inspect and palpate the vaginal opening of the fistula. Any local genital infection was treated before surgery. Cystoscopy was done to establish the supratrigonal location of the fistula and assess its proximity to the ureteric orifices. An excretory urogram was performed in selected patients where ureteric orifices were too close to VVF. One patient had bilateral and 2 patients had unilateral ureteric orifice involvement.

For this procedure, the patient is placed in trendelenberg position. The abdomen is opened via an infraumbilical midline/Pfannensteil incision. The peritoneum is opened to approach the posterior surface of bladder. The bowel is gently packed with sponges before the cystotomy and effective suction is used to minimize urinary spillage. To elevate the posterior bladder wall, full thickness stay sutures are placed, using 3/0 chromic catgut, at the lower end of posterior wall of the bladder. An 18F Foley catheter is put in the bladder perurethrally, prior to placement of stay sutures, and the balloon is inflated upto 40-50 cc. It facilitates the perception of thickness of posterior bladder wall while placing full thickness stay sutures and at the same time prevents entrapment of anterior bladder wall. A short cystotomy beginning about 2-3 cms away from cul-de-sac is made in between these stay sutures, limited to the posterior bladder wall (Fig. 2). Routinely we use three fine malleable daever retractors to enhance the intra vesical visibility by appropriate retraction within the cystotomy. The shorter cystotomy does not compromise vision.

The proximity of the ureteric orifice to the VVF is assessed at this stage and only in those cases where orifice sits close to the fistula edge, a 5-6 Fr infant feeding tube is passed into the ureters before fistula dissection is commenced. As the dissection progresses towards and around the fistula, additional stay sutures are placed along the edges of the cystotomy at mirror image locations. These stay sutures later on act as guide for approximation of cystotomy edges. Apart from providing effective anchorage to lift up the posterior bladder wall, they also minimize oozing from the cystotomy edges, and are thus haemostatic.

In a small fistula, the cystotomy is extended to encircle the fistula and excision of the fistula is done as the traditional

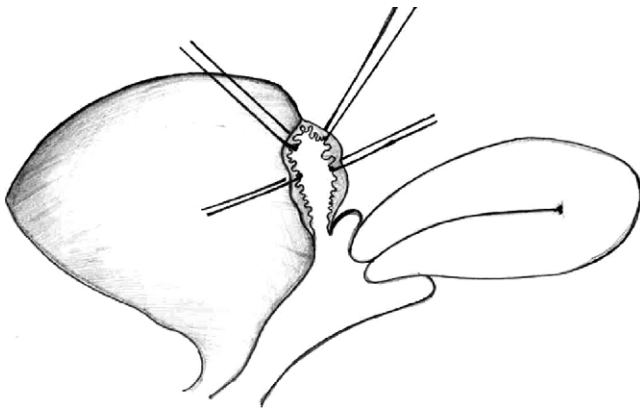


Fig. 2 – The cystostomy is made only on the posterior bladder wall in between stay sutures.

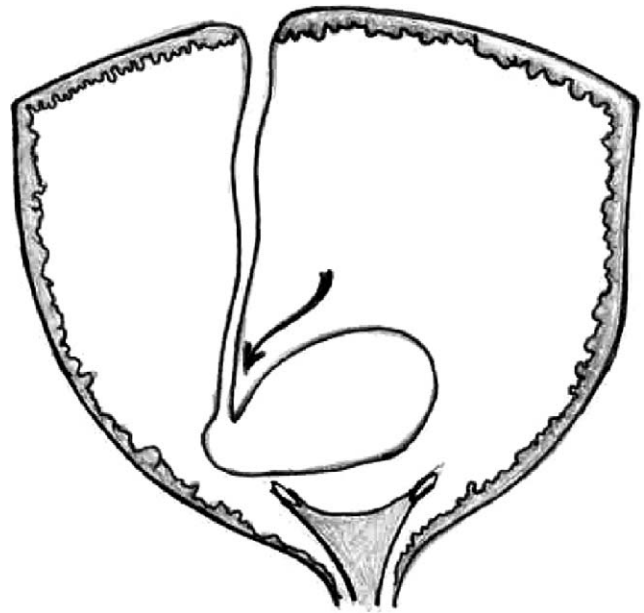


Fig. 4 – The medial portion of the bladder edge after excision of fistula forms a flap.

107 technique. If the fistula is large (>2.5 cm), the cystostomy is
 108 directed in parasagittal line towards one side of the fistula
 109 (Fig. 3). It leads to formation of a flap of bladder wall after the
 110 fistula is excised (Fig. 4). This flap is subsequently rotated to
 111 close the bladder wall defect (Fig. 5). Complete excision of the
 112 fistula is done and the plane between bladder and vaginal wall
 113 is dissected as in traditional O'Connor's procedure. This
 114 method of bladder closure ensures a tensionless suture line
 115 (Fig. 6). The vaginal wall is closed in single layer with
 116 continuous interlocking, closely placed stitches using either
 117 1'0/2'0' polyglecaperone (monocryl) or polyglactin (vicryl) in a
 118 transverse line. Greater omentum is mobilized and is
 119 anchored to anterior vaginal wall to completely cover the
 120 vaginal suture line. In 2 patients, where omentum was
 121 considered insufficient, paravesical peritoneal flaps were used

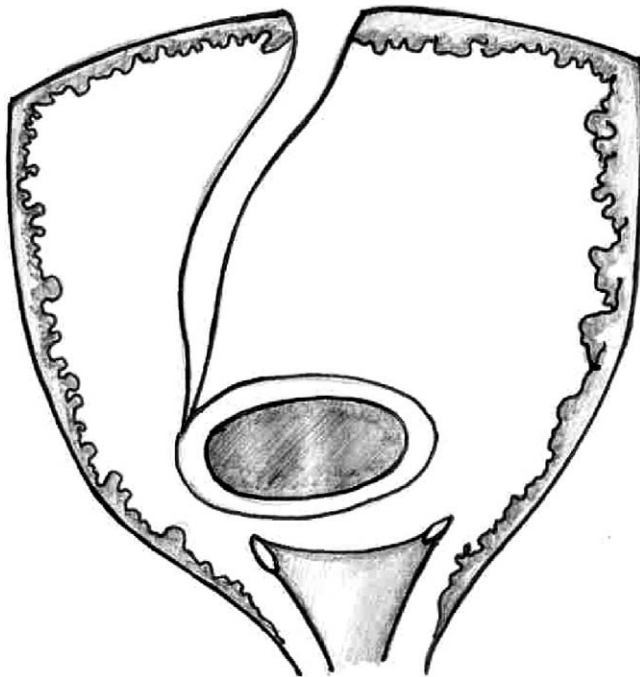


Fig. 3 – The cystostomy is extended in parasagittal line to one side, in case of a large fistula.

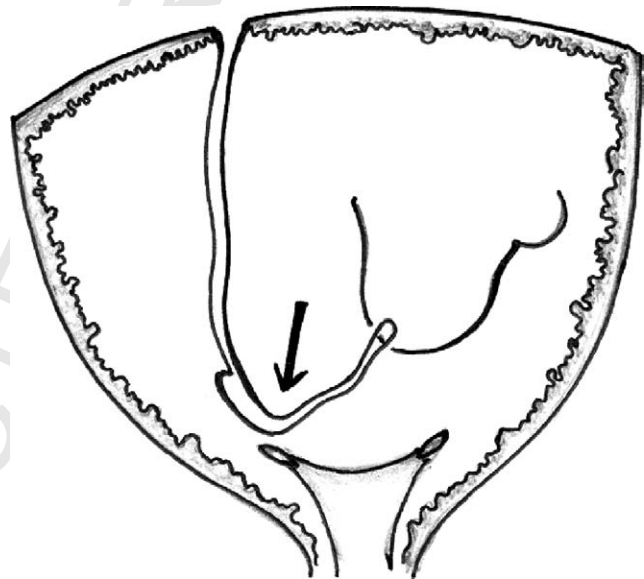


Fig. 5 – The bladder flap is rotated and advanced into the defect.

for interposition. The urinary bladder is also closed in single
 122 layer using 3'0' polyglecaperone or polyglactin by continuous
 123 interlocking, closely placed stitches. Suprapubic cystostomy
 124 (SPC) and per urethral catheters are placed to drain the bladder
 125 and the cystostomy is closed. The SPC is extraperitonealized
 126 and the laparotomy wound is closed in layers. No drain is
 127 placed routinely.
 128

The suprapubic catheter is removed after 2 weeks and the
 129 per urethral catheter is removed after 3 weeks. The patients
 130

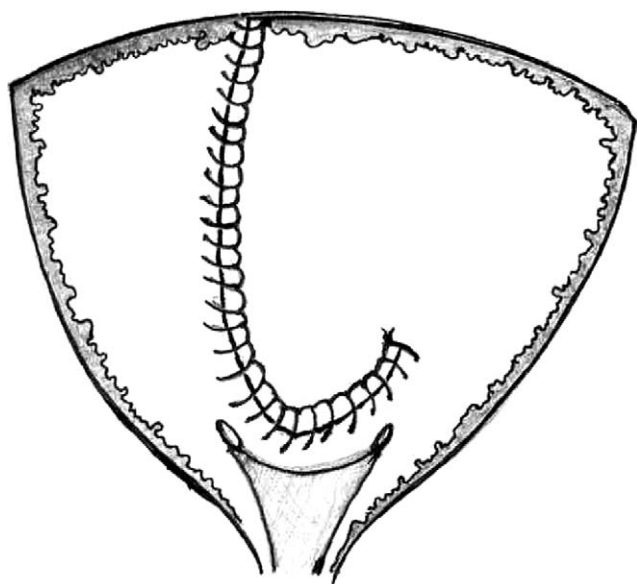


Fig. 6 - The bladder flap achieves tensionless suture line in the bladder wall.

131 are advised for sexual abstinence for 3 months. All patients
 132 were advised to void at frequent intervals to prevent over
 133 distension of the bladder. Patients desiring future pregnancy
 134 were advised strict antenatal monitoring, regular follow up in
 135 the antenatal clinic and elective caesarean section.

136 3. Results

137 Mean age of our patients was 21.4 (range-18 to 41)
 138 years. Four patients had fistula after hysterectomy
 139 (2-transvaginal hysterectomy and 2 transabdomi-
 140 nal), while 22 patients had a VVF following
 141 manipulations for obstructed labour. Twenty out
 142 of 22 patients who had obstructed labor were short
 143 statured (height less than 5 feet). Nine patients had
 144 recurrent VVF, following previous attempts at
 145 repair. Four out of them had undergone transvaginal
 146 repair and 5 were treated transabdominally at
 147 peripheral centers (no records were available). One
 148 case had developed VVF 8 years earlier and had
 149 undergone three previous failed attempts at repair,
 150 twice vaginally and once transabdominally.

151 Mean fistula size was 2.8 cm (range 1.0 to 3.7).
 152 Three fistulae were encroaching the ureteric orifice
 153 and they required additional ureteroneocystostomy.
 154 Eighteen patients had a larger fistula (>2.5 cm) and
 155 were managed using parasagittal cystotomy. All of
 156 them achieved tensionless closure using the above
 157 technique. It was possible to interpose greater
 158 omentum in 24 cases whereas in 2 patients the
 159 omentum was small and atrophic hence vascular-
 160 ised paravesical peritoneal flap was used.

161 Transurethral cystolitholapaxy was done in 2
 162 patients having vesical calculi 2-3 weeks prior to
 163 VVF closure. Thus the bladder wall edema asso-
 164 ciated with stone was negligible at the time of repair
 165 and local tissue vitality was good.

166 Mean operative time was 104 minutes, intra
 167 operative blood loss was insignificant and none of
 168 the patients required postoperative blood transfu-
 169 sion.

170 All patients were dry after 2 weeks of suprapubic
 171 and per urethral catheter drainage. The patients
 172 were followed up regularly in our out patients
 173 department, and were largely asymptomatic except
 174 some irritative lower urinary tract symptoms in 6
 175 cases which settled spontaneously in 4-6 weeks.
 176 Postoperative micturating cystogram was done only
 177 in selected patients to document dryness. Since
 178 majority of our patients were young (mean age-21.4
 179 years) and were desirous of future pregnancy all
 180 patients were advised caesarean section. Four
 181 patients became pregnant and had a successful
 182 outcome of pregnancy by elective caesarean section,
 183 with no resultant urological infirmity. Only 1 had
 184 stress urinary incontinence associated with urethral
 185 incompetence. She later on underwent colposus-
 186 pension and was relieved. Laparotomy wound was
 187 infected in 1 patient, which healed by secondary
 188 intention. No patient on follow up complained of
 189 features suggestive of adhesive intestinal obstruc-
 190 tion, prolonged ileus or peritonitis. Only 21 patients
 191 reported for follow up after 1-5 years and they were
 192 urologically asymptomatic and continent. Three
 193 patients had dysparaunia prior to surgery, possibly
 194 due to previous surgery, which was not relieved.

195 4. Discussion

196 O'Connor's technique is advocated as the gold
 197 standard technique for managing supratrigonal
 198 VVF [10]. Traditional technique described by O'Con-
 199 nor involves extraperitoneal approach to the urinary
 200 bladder [11]. It involves dissection of the urinary
 201 bladder extraperitoneally in the retro pubic space. A
 202 longitudinal cystotomy is made on the anterior wall
 203 of bladder, which is advanced, coursing through the
 204 dome of the bladder, backwards towards the fistula.
 205 It results in a long cystotomy which almost bivalves
 206 the bladder. The vaginal wall is closed in 2 layers and
 207 a vascularised tissue is often interposed in between
 208 before the closure of bladder. It can be local pelvic
 209 tissue, retro pubic fat or the greater omentum after
 210 opening up the peritoneal cavity. Recently use of
 211 free grafts has also been described [12]. Ureteric
 212 catheters are placed and the bladder is closed over

Table 1 – Advantages and disadvantages of our modifications of the O'Connor's technique

Advantages	Disadvantages
1-Shorter cystotomy, avoids bivalving	1-Limited vision
2-Decreased blood loss	2-Needs expertise
3-Decreased operating time	
4-Decreased risk of anesthesia	
5-Decreased postoperative voiding dysfunction	
6-Preservation of retro pubic space for future SUI surgery	
7-Drainage of retro pubic space not required	
8-Suture economy	
9-Option to tailor the cystotomy in sagittal/parasagittal plane to achieve tensionless closure of large fistula.	
10-Early assessment of omentum	

suprapubic and per urethral catheters. A drain is put in the reteropubic space.

The modifications, we used in our patients consisted of approaching the bladder transperitoneally (without doing any dissection in retro pubic space), which provides quick access to the posterior wall of the bladder. Stay sutures provide effective anchorage to lift up the posterior wall and minimize the oozing from the cystotomy edges. The cystotomy is very small and avoids classical bivalving of the bladder, which accounts for increased blood loss and prolonged operative time. Some people have even speculated its role in enhancing postoperative voiding dysfunction and reflux [12].

It is also possible to direct the cystotomy in parasagittal line if the fistula is large and medial side of the bladder may be rotated as a flap into the bladder defect. Thus, it minimizes the traction on the lateral edges of the bladder defect, which is inevitable when such a large fistula is closed using sagittal cystotomy. The fistulous edges are excised and the closure of both vaginal as well as bladder defect is done in single layer using closely placed interlocking stitches. We prefer to use polyglecaprone (monocryl) for this purpose as it glides through the tissues without any abrasive effect. Approaching the urinary bladder directly through the peritoneum has not added to peritonitis, adhesive intestinal obstruction or prolonged ileus, instead it allows an early inspection of omentum and offers a wider field of vision for the surgeon. The urinary spillage is negligible and of no consequence. A table enumerating the advantages and disadvantages of our modifications is enlisted (Table 1). We prefer to use omental interposition in all patients. In case it is short or atrophic we have used paravesical fat/peritoneal flap.

Our approach has given us 100% success in terms of achieving continence. Ever since transabdominal approach to VVF has been described, [13] continuous refinements in the technique have given better results. Several surgical techniques have been used

in these cases with failure rates ranging from 4 to 35% [14,15]. Nesrallah LJ evaluated the success rate of transperitoneal O'Connor's procedure to be 100% [10] and consider it to be the gold standard for supratrigonal fistulae. In a series of 23 VVFs, Cetin concluded that the fistulas located above the interureteric ridge and fistulas encroaching the ureteric orifices, were good candidates for suprapubic approach [16]. In a series of 68 VVFs, Motiwala and colleagues attributed the success of transvesical technique to simple access, construction of a vascularised flap and utilization of vicryl suture [17]. A recent review by Huang has emphasized the importance of individually tailoring the technique and approach for each fistula [18]. Regardless of whether a transabdominal or transvaginal approach is selected, the concepts of using healthy tissue, tension free closures and reinforcing the closures in high risk situations will ensure success nearly in all times. Transabdominal-transvesical approach is the preferred method of managing large supratrigonal VVFs [6,7]. Mondet evaluated the anatomic and functional results of transperitoneal-transvesical fistula repair and concluded that it to be the reference treatment for complex supratrigonal VVFs [8]. Leng and coworkers also reported that limited transvesical repair of uncomplicated supratrigonal VVFs offers reliable success with minimal morbidity and hospital stay comparable to the transvaginal approach [9]. Recently laparoscopic VVF repairs are gaining importance [19]. Consensus is emerging that laparoscopic repair of VVF is feasible and efficacious. The modified O'Connor's approach as described by us may be adopted in laparoscopic surgery as well.

5. Conclusion

Vesicovaginal fistulas represent a distressing urological condition for the patient and demand meticulous skilled surgical attention [20,21]. We

294 have suggested some modifications to the original
 295 technique of O'Connor's repair by approaching the
 296 fistula transperitoneally, making a smaller cystot-
 297 omy limited to the posterior wall, liberal use of stay
 298 sutures to enhance exposure and reduce bleeding,
 299 using parasagittal cystotomy in large VVFs and
 300 totally avoiding reropubic dissection and drain.
 301 These modifications have minimized intraoperative
 302 blood loss and operating time without compromis-
 303 ing the exposure and ultimate outcome. Since the
 304 retropubic space is not disturbed, it leaves the option
 305 for subsequent SUI surgery. The modifications are
 306 simple to understand and easily practicable.

307 References

- 308 [1] Tancer ML. Observations on prevention and management
 309 of vesico-vaginal fistula after total hysterectomy. *Surg*
 310 *Gynecol Obstet* 1992;175:501-6.
- 311 [2] Lee AL, Symmonds RE, Williams TJ. Current status of
 312 genitourinary fistula. *Obstet Gynecol* 1988;72:313-9.
- 313 [3] Gilmour DI, Dwyer PL, Carey MP. Lower urinary tract
 314 injury during gynecologic surgery and its detection by
 315 intraoperative cystoscopy. *Obstet Gynecol* 1999;94:883-9.
- 316 [4] Bhandari M, Dalela D. Complexities of a vesicovaginal
 317 fistula. *Arch Esp Urol* 1994;47(3):303-6.
- 318 [5] Dalela D, Goel A, Sankhwar SN, Singh KM. Vesical calculi
 319 with unrepaired vesicovaginal fistula: A clinical appraisal
 320 of an uncommon association. *J Urol* 2003;170:2206-8.
- 321 [6] Diaz CE, Calatrava GS, Caldentey GM, Moreno PF, Lapuerta
 322 TE, Garcia VF. Surgical repair of vesico-vaginal fistula with
 323 abdominal transvesical approach. Comments on this techni-
 324 que and long-term results. *Arch Esp Urol* 1997;50:55-60.
- 325 [7] Sanchez JM, Gullian MC, Parra ML, Gomez SC, Laguna MP,
 326 Garcia AJ. Transvesical repair of non-complicated vesico-
 327 vaginal fistula. *Actas Urol Esp* 2000;24:185-9.
- 328 [8] Mondet F, Chartier EJ, Conrot P, Bitker MO, Chatelain C,
 329 Richard F. Anatomic and functional results of transper-
 330 itoneal- transvesical vesico-vaginal fistula repair. *Urology*
 331 2001;58:882-6.
- 332 [9] Leng WW, Amundsen CL, McGuire EJ. Management of
 333 female genitourinary fistulas: transvesical or transvaginal
 334 approach. *J Urol* 1998;160:1995-9.
- 335 [10] Nesrallah LJ, Srougi M, Gittes RF. The O'Connor technique:
 336 the gold standard for supratrigonal vesicovaginal fistula
 337 repair. *Urology* 1999;161(2):566-8.
- 338 [11] O'Connor VJ. Review of experience with vesicovaginal
 339 fistula repair. *J Urol* 1980;123:367-9.
- 340 [12] El-Lateef Moharram AA, El-Raouf MA. Retropubic repair of
 341 genitourinary fistula using a free supporting graft. *BJU Int*
 342 2004 Mar;93(4):581-3.
- 343 [13] Legueu F. La voie trans-peritoneo-vesicale pour la cure de
 344 certaines fistules vesico-vaginales operatoires. *Arch Urol*
 345 *Clin Necker* 1914;1:1.
- 346 [14] Goodwin WE, Scardino PT. Vesicovaginal and ureterova-
 347 ginal fistulas: a summary of 25 years of experience. *J Urol*
 348 1980;123:370.
- 349 [15] Kristensen JK, Lose G. Vesicovaginal fistulas: the transper-
 350 itoneal repair revisited. *Scand J Urol Nephrol* 1994;157:101.
- 351 [16] Cetin S, Yazicioglu A, Ozgur S, Ilker Y, Dalva I. Vesicova-
 352 ginal fistula repair: a simple suprapubic transvesical
 353 approach. *Int Urol Nephrol* 1988;20:265-8.
- 354 [17] Motiwala HG, Amlani JC, Desai KD, Shah KN, Patel PC.
 355 Transvesical vesicovaginal fistula repair: a revival. *Eur*
 356 *Urol* 1991;19:24-8.
- 357 [18] Huang WC, Zinman LN, Bihrlle III W. Surgical repair of
 358 vesico-vaginal fistulas. *Urol Clin North Am* 2002;29:709-23.
- 359 [19] Sotelo R, Mariano MB, Garcia-Segui A, Dubois R, Spaliviero
 360 M. Laparoscopic repair of vesicovaginal fistula. *J Urol*
 361 2005;173(5):1615-8.
- 362 [20] Blaivas JG, Heritz DM, Rominzi LI. Early versus late repair of
 363 vesicovaginal fistulas: vaginal and abdominal approaches.
 364 *J Urol* 1995;153:1110-3.
- 365 [21] Zimmern PE, Ganabathi K, Leach GE. Vesicovaginal fistula
 366 repair. *Urol Clin North Am* 1994;2:87-99.
- 367
 368